

## Cessation of craniofacial growth and timing of implant placement in the esthetic zone – a systematic review

### Zakończenie wzrostu kości czaszki trzewnej a termin implantacji w strefie estetycznej – przegląd systematyczny

<sup>1</sup> Private practice, Warsaw, Poland

<sup>2</sup> Department of Orthodontics and Dentofacial Orthopedics, University of Bern, Switzerland and Department of Orthodontics, Palacky University Olomouc, Olomouc, Czech Republic

#### Abstract

**Aim.** Dental implants behave like ankylosed teeth, i.e. they do not adapt to remodelling of the bone and the eruption of adjacent teeth. Thus, they should be placed once craniofacial growth is complete. Several studies demonstrated that craniofacial growth might continue into adulthood. Therefore, the objective of this study is to systematically review the findings of publications quantifying craniofacial growth after puberty.

**Material and methods.** The PubMed and Embase databases were searched for longitudinal studies in which the facial growth in males > 17 years old and females > 16 years old was assessed on lateral cephalometric radiographs. Two researchers performed the search independently of each other. The methodological quality of the studies was assessed according to a grading system developed by the Swedish Council on Technology Assessment in Health Care.

**Results.** Fourteen studies were selected. The maximum increase of anterior facial height (Nasion-Menton distance) in males was 4.3 mm. This change occurred over a period of 30 years (from 17 to 47 years of age; 0.14 mm per year). The maximum increase of the Nasion-Menton distance in females was 4.5 mm (0.15 mm per year). The maximum increase of lower anterior facial height (ANS-Menton) in males was 2.5 mm (0.08 mm per year). The maximum increase of ANS-Menton in females was 3.2 mm (0.1 mm per year).

**Conclusions.** Based on the findings we conclude the following: (1) the growth of the craniofacial skeleton after 17 years of age in males and 16 years of age in females is relatively small and should have a limited effect on the long-term esthetics of implant-crowns; (2) caution is recommended when considering implantation in patients with a gingival display upon smiling and those having inadequate occlusal contacts between maxillary and mandibular teeth.

**Keywords:** esthetic zone, craniofacial growth, intraosseous implants, bone remodelling.

#### Streszczenie

**Wprowadzenie.** Implanty dentystyczne zachowują się tak, jak zęby ankylotyczne, tj. nie przystosowują się do przebudowującej się kości oraz wzrastających zębów sąsiednich. Z tego powodu winny być stosowane wtedy, kiedy wzrost kości czaszki trzewnej jest ukończony. Niektóre badania wykazują, że wzrost kości twarzoczaszki może występować również w okresie dorosłości. Celem tej pracy jest przegląd systematyczny dostępnej literatury pod kątem odnalezienia badań oceniających wzrost kości twarzoczaszki po okresie pokwitania.

**Materiał i metody.** Bazy artykułów PubMed oraz Embase zostały przeszukane celem odnalezienia badań wzdłużnych, w których na podstawie bocznych teleradiogramów głowy oceniany był wzrost kości czaszki trzewnej u mężczyzn starszych niż 17 oraz u kobiet starszych niż 16 lat. Dwóch badaczy przeprowadziło przeszukiwanie PubMed oraz Embase niezależnie od siebie. Metodologia włączonych badań oceniona została zgodnie z wytycznymi *Swedish Council on Technology Assessment in Health Care*.

**Wyniki.** W trakcie poszukiwań znaleziono 14 publikacji. Maksymalny wzrost przedniego odcinka czaszki trzewnej (Nasion-Menton) u mężczyzn wyniósł 4,3 mm. Ta zmiana wystąpiła w okresie 30 lat (od 17 do 47 roku życia; tzn. 0,14 mm na rok). Maksymalny wzrost odcinka Nasion-Menton u kobiet wyniósł 4,5 mm (0,15 mm na rok). Maksymalny wzrost dolnego odcinka czaszki trzewnej (ANS-Menton) u mężczyzn wyniósł 2,5 mm (0,08 mm na rok). Maksymalny wzrost dolnego odcinka czaszki trzewnej (ANS-Menton) u kobiet wyniósł 3,2 mm (0,1 mm na rok).

**Wnioski.** Wzrost kości czaszki trzewnej u kobiet po 16 oraz mężczyzn po 17 roku życia jest stosunkowo niewielki i może mieć ograniczony wpływ na estetykę uzupełnień protetycznych opartych na implantach; jednakże należy być ostrożnym w wyborze metody leczenia / terminu implantacji w przypadkach, gdy planuje się implantację u pacjentów z tzw. uśmiechem dziąsłowym oraz u pacjentów posiadających niepełne kontakty okluzyjne pomiędzy zębami żuchwy i szczęki.

**Słowa kluczowe:** strefa estetyczna, wzrost czaszkowo-twarzowy, implanty śródkostne, przebudowa kości.

#### Introduction

In recent years dental implants have become a reliable method for replacing missing teeth [1–3].

The first implant system was introduced more than 40 years ago [4] and was based on the principle of osseointegration i.e. direct integration of the

implant and the bone by forming osseous tissue around the implant [5, 6]. It has been shown numerous times that dental implants are stable in the long-term and failures are rare [7]

The success of treating a patient with an implant-supported restoration also depends on the appearance of the whole region where the implant-supported restoration was made: implant-crown, adjacent teeth, and surrounding soft tissues. Achieving lasting esthetic results can be particularly challenging in still growing patients [8, 9]. This is because implants remain immobile in the bone [10], i.e. they do not adapt to the surrounding bone and soft tissue when they remodel during growth. As a result infraocclusion of the implant-crown develops. This, in turn, can lead to functional and esthetic problems especially when the implant is placed in the esthetic zone (incisors and canines in the maxilla) [11, 12]. In order to prevent this unwanted sequel, it is common to defer implant placement until skeletal growth is complete, typically when a patient is > 20 years old [13]. It has been reported, however, that craniofacial growth can continue even into adulthood [14] and is accompanied by a slight continuous eruption of teeth [15]. Therefore delaying implantation until the patient turns, for example, 21 years may not preclude the development of infraocclusion of the implant-crown [16, 17].

Despite these reports saying that craniofacial growth is not complete in many adults, several longitudinal studies assessing craniofacial growth in adulthood have demonstrated that only limited growth changes should be expected in the 3rd decade of life [18]. These contradictory findings increase the uncertainty regarding when the optimal time to place dental implants is, particularly in the esthetic zone. Therefore the purpose of this study is to systematically review the findings of publications quantifying craniofacial growth after puberty.

## Material and Methods

### Search strategy

Relevant publications were identified by a search of two electronic databases: PubMed and EMBASE. A list of terms and the search strategy were developed, and the databases were selected, with the help of a senior librarian who specializes in health sciences. The electronic search was applied to PubMed (1966 – November 2016) and adapted for EMBASE (1980 – November 2016). The last search was performed on 24 November 2016. No language restrictions were imposed.

The literature search was conducted following a concatenated search strategy:

Step #1. (Maxillofacial development[MeSH Terms] OR maxillofacial development[tiab] OR

maxillofacial growth[tiab] OR facial bones[MeSH Terms] OR facial bone[tiab] OR facial bones[tiab] OR mandible[tiab] OR maxilla[tiab] OR alveolar[tiab] OR dentoalveolar[tiab].

Step #2. (Growth and development[Subheading] OR growth[tiab] OR growth[MeSH Terms] OR development[tiab].

Step #3. (Cephalometry[MeSH Terms] OR cephalometry[tiab] OR cephalometric[tiab].

Step #4. (Longitudinal studies[Mesh] OR Longitudinal[tiab] OR follow-up[tiab] OR followup[tiab].

Step #5. (Adolescent[Mesh] OR Adult[Mesh] OR (young adult[tiab] OR young adults[tiab] OR adolescent[tiab] OR adolescent-s[tiab] OR (adolescence[tiab] OR midadulthood[tiab] OR (postadolescent[tiab] OR post-adolescent[tiab].

Step #6. #1 AND #2 AND #3 AND #4 AND #5.

### Study selection

Based on the titles and abstracts retrieved by query #6, both authors selected publications according to the following *inclusion criteria*:

- studies in humans,
  - prospective or retrospective original studies
  - longitudinal observation of subjects,
  - lateral cephalograms used for assessment of growth,
  - at least two observations after 17 years (males) or 16 years (females).
- The following *exclusion criteria* were used:
- cross-sectional studies,
  - studies that evaluated growth in patients with congenital malformations (syndromes) or systemic diseases,
  - studies that evaluated growth in patients who had had trauma or orthognathic surgery,
  - animal studies,
  - reviews,
  - case reports and letters to the editor.

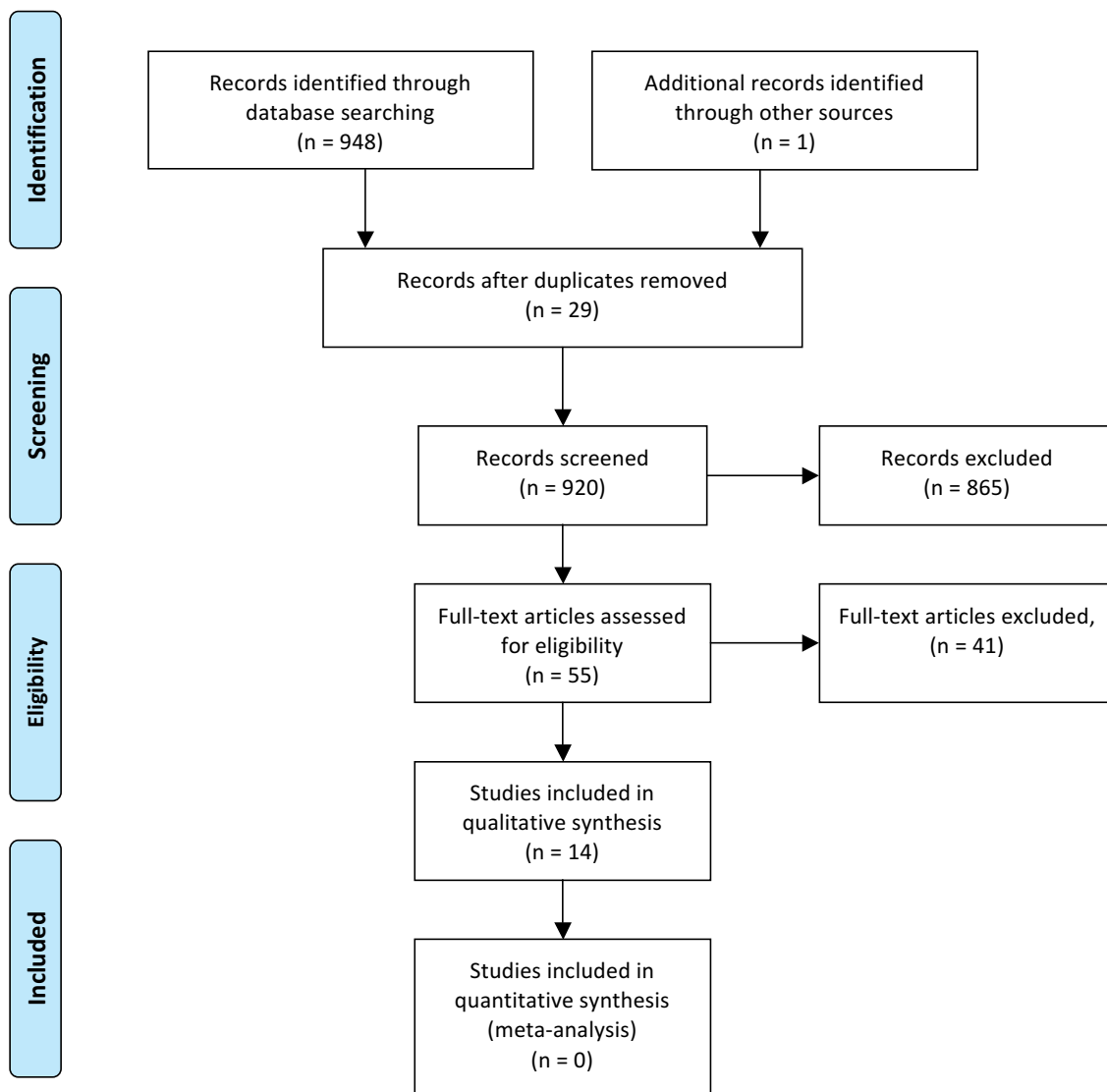
The abstracts were scored as *Relevant*, *Irrelevant*, or *Unclear* after review of title and abstract only. Then, the articles that apparently met the inclusion criteria (*Relevant*) and articles of which title or abstract did not present enough relevant information (*Unclear*) were retrieved full text and reviewed according to all the inclusion/exclusion criteria. The reference lists of included articles were perused and references that appeared relevant were followed up. Finally, the “Related citations” tool of the PubMed was used to identify articles related to the included studies and meeting the inclusion criteria. Only titles and abstracts of the first 40 related articles were reviewed.

**Data extraction**

A data extraction sheet was developed. Both authors independently extracted the following data from the included studies: author(s), year of publication, number of subjects and sex distribution, ethnic background, age at successive observations, value of cephalometric measurements at successive observations, change of cephalometric variables during the observation period, and the yearly increment of the change of cephalometric variables during the observation period. In case of disagreement between authors regarding inclusion/exclusion of a study, a discussion was held until agreement was reached.

**Quality assessment and level of evidence**

According to the Centre for Reviews and Dissemination (2009), flaws in the design or conduct of a study can result in bias, and in some cases this can have as much influence on the observed effects as that of the treatment. Thus, an evaluation of methodological quality gives an indication of the strength of evidence provided by the study. However, no single approach to assessing methodological soundness is appropriate to all systematic reviews. The best approach should be determined by contextual, pragmatic and methodological considerations (Centre for Reviews and Dissemination, 2009).

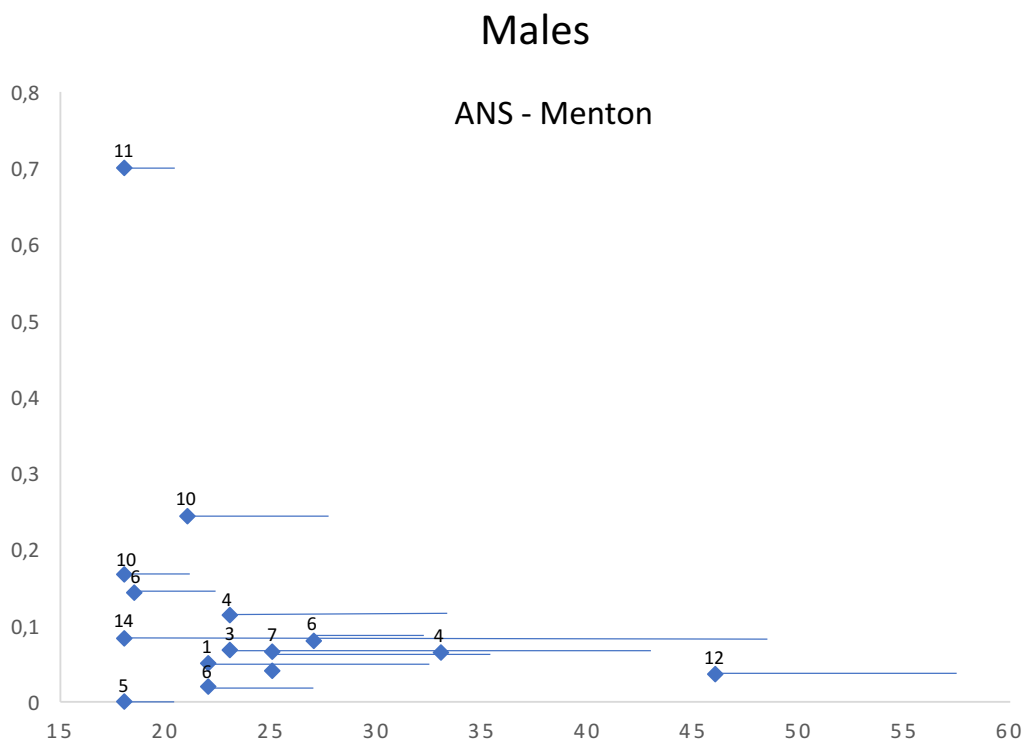
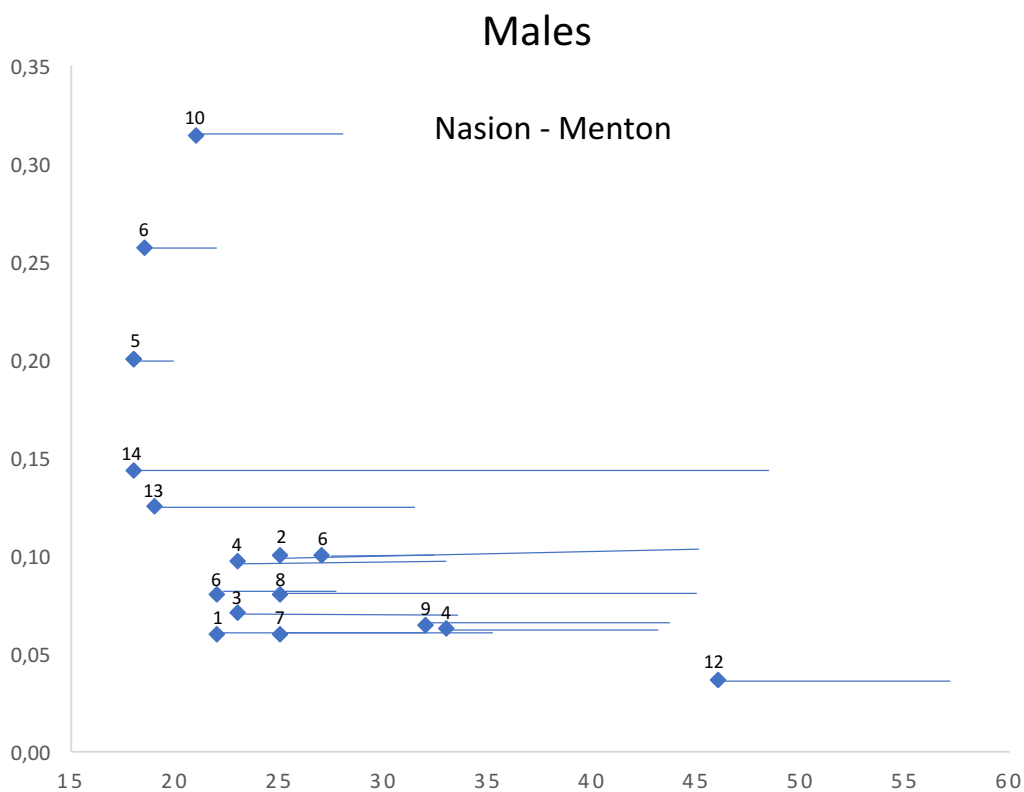


From: Moher D, Liberati A, Tetzlaff J, Altman DG, The PRISMA Group (2009). Preferred Reporting Items for Systematic Reviews and Meta-Analyses: The PRISMA Statement. PLoS Med 6(7): e1000097. doi:10.1371/journal.pmed1000097

For more information, visit [www.prisma-statement.org](http://www.prisma-statement.org).

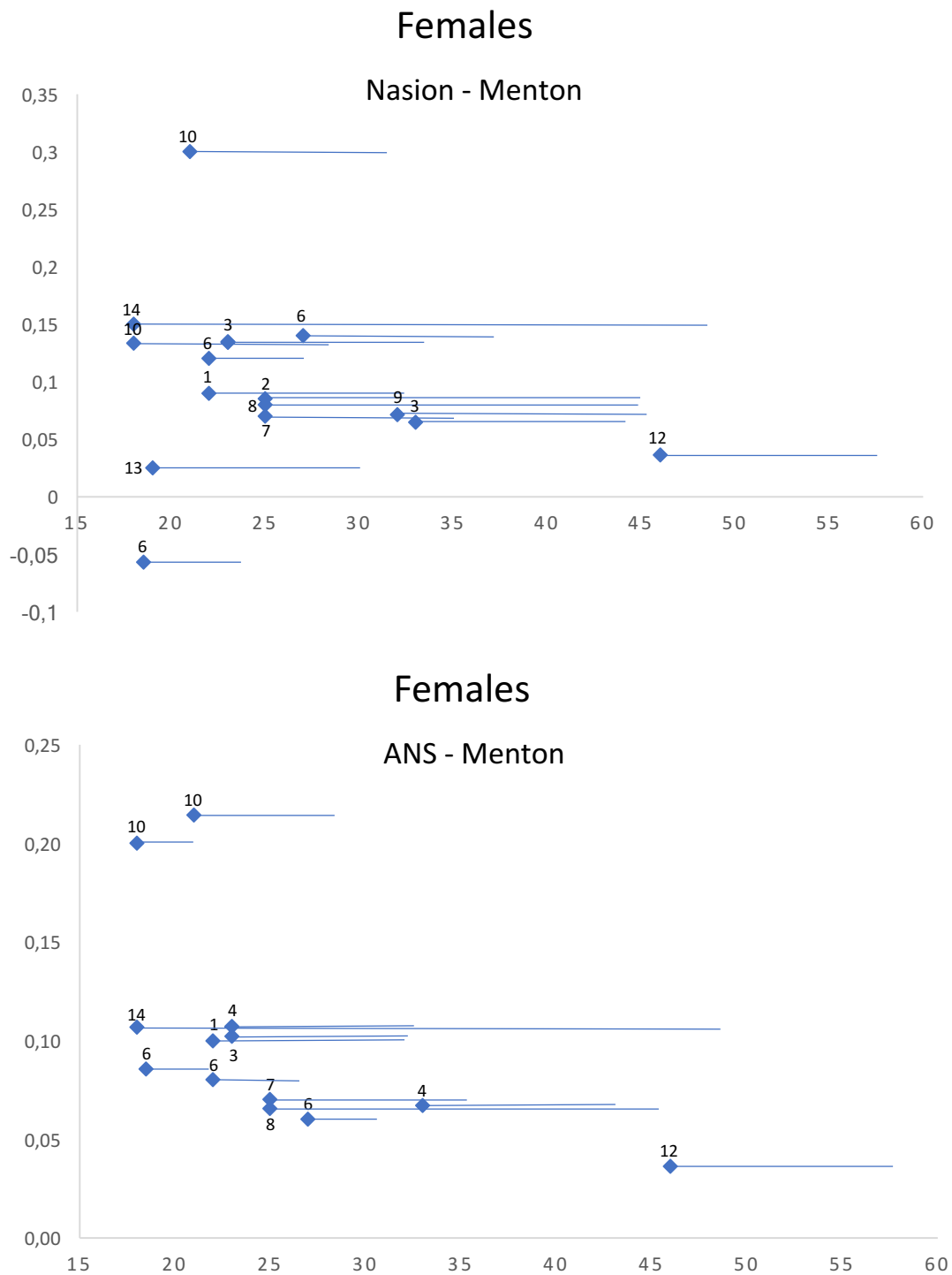
**Figure 1.** PRISMA 2009 Flow Diagram representing the search for relevant articles

**Rycina 1.** Schemat kroków PRISMA 2009 w procesie poszukiwania odpowiednich artykułów



**Figure 2.** A visual representation of the annualized changes found in different studies in males. The position of the rhombus is defined by the age when the observation started (X axis) and the mean annual growth increment (Y axis). The length of the horizontal bar corresponds to the length of the observation period. The numbers in the graphs denote particular studies

**Rycina 2.** Graficzne przedstawienie zmian obserwowanych u mężczyzn na przestrzeni lat a ujętych w różnych badaniach. Pozycja rombu na osi X odpowiada początkowi obserwacji, a na osi Y – średniemu rocznemu wzrostowi. Długość linii horyzontalnej koresponduje z czasem trwania obserwacji



**Figure 3.** A visual representation of the annualized changes found in different studies in females. The position of the rhombus is defined by the age when the observation started (X axis) and the mean annual growth increment (Y axis). The length of the horizontal bar corresponds to the length of the observation period. The numbers in the graphs denote particular studies

**Rycina 3.** Graficzne przedstawienie zmian obserwowanych u kobiet na przestrzeni lat a ujętych w różnych badaniach. Pozycja rombu na osi X odpowiada początkowi obserwacji, a na osi Y – średniemu rocznemu wzrostowi. Długość linii horyzontalnej koresponduje z czasem trwania obserwacji

The authors assessed the methodological quality of the included studies according to a grading system developed by the Swedish Council on Technology Assessment in Health Care [19], which was based on the criteria for assessing study qu-

ality from the Centre for Reviews and Disseminations in York, United Kingdom [20]. The methodological quality criteria are listed as followed:

- *Grade A (high)* – RCT or prospective study with a well-defined control group; Defined diagnosis

and end points; Diagnostic reliability tests and reproducibility tests described; Blinded outcome measurements (all criteria should be met)

- *Grade B (moderate)* – Cohort study or retrospective case series with a defined control or reference group; Defined diagnosis and end points; Diagnostic reliability tests and reproducibility tests described (all criteria should be met, if not, grade C)
- *Grade C (low)* – One or more of the following conditions: large attrition of the sample, unclear diagnosis and end points, poorly defined patient material.

The final level of evidence for each conclusion was judged according to the following scale [21]:

- *Strong scientific support (evidence grade 1)* – Conclusion based on at least two studies with level A evidence. Studies with opposite conclusions may lower the evidence grade.
- *Moderately strong support (evidence grade 2)* – Conclusion based on one study with strong evidence (A) and at least two with moderately strong evidence (B). Studies with opposite conclusions may lower the evidence grade.
- *Limited scientific support (evidence grade 3)* – Conclusion based on at least two studies with moderately strong evidence (B). If studies contradicting the conclusion exist, the scientific basis is judged as insufficient or contradictory.
- *Inconclusive scientific support (evidence grade 4)* – If studies fulfilling the evidence criteria are lacking, the scientific basis for conclusion is considered insufficient.

## Results

The search strategy resulted in the retrieval of 948 publications. The application of inclusion/exclusion criteria (**Figure 1**) allowed the identification of 14 relevant studies, of which 13 were found through electronic search and 1 was identified through hand searching.

The main reasons for exclusion were inappropriate age of assessment (below 17 for males and 16 for females) in 20 publications and the evaluation of soft tissues only in 6 publications.

Seven hundred twenty four males and 345 females (in total, 1069 subjects) were examined. The sample size in all studies was similar and ranged from 28 [18] to 164 subjects [22]. The age range was from 17.5 years [23] to 47.3 years [23] for males and from 17.2 years [23] to 48.3 years [23] for females.

The maximum increase of anterior facial height (N-Me) in males was 4.3 mm [23]. This change occurred over a period of 30 years (from 17 to 47 years of age), thus the annualized increase of N-Me was 0.14 mm (**Figures 2, 3**). The maximum increase of

N-Me in females was 4.5 mm [23] and the annualized change was 0.15 mm. The maximum increase of lower anterior facial height (ANS-Me) in males was 2.5 mm [23]. This change occurred over a period of 30 years (from 17 to 47 years of age), thus the annualized increase of ANS-Me was 0.08 mm. The maximum increase of ANS-Me in females was 3.2 mm [23] and the annualized change was 0.1 mm.

The methodological quality of the studies was good or moderate. The assessment scores ranged from 50% to 58% of the maximum score (15 points), with an average of 54%. In most cases, satisfactory scores were obtained for the following criteria: adequate sample size (B), appropriate measurements (H), and appropriate reliability of the method (J). However, satisfactory scores were never obtained for some criteria; such as estimation of appropriate sample size before data collection (C), prospective study design (F), blind measurements (I), and providing confidence interval (O).

## Discussion

Obtaining an optimal result for treatment with implant-supported restoration in the esthetic zone is difficult because the restored tooth should not differ from a natural one. Moreover soft tissues in the region of restoration should match the soft tissues in the region of a contralateral tooth. Thus, a clinician should strive to achieve the overall symmetry of the dental arch. Front teeth should exhibit symmetry from left to right with no tooth differing from its counterpart on the opposite side of the dental arch. The color, texture, shape, translucency, and crown proportions of the teeth should match. The gingival margin should follow the positions of the cemento-enamel junctions of the teeth with the left side symmetrical to the right. Furthermore, the incisal margins of the upper teeth should follow the contour of the inferior lip. Some clinicians imply that "the golden ratio" (i.e. the ideal ratio of the width of six anterior teeth exposed on smiling) is respected [24, 25, 26]. Even if all these requirements are met, craniofacial growth occurring after implant placement could destroy the perfect outcome of treatment. Typically, a step between the incisal edges of implant-crown and adjacent teeth develops and the contour of the marginal gingiva in the region of the implant-supported restoration is disturbed. Unfortunately, Bernard et al. (2004) demonstrated that the infraocclusion of implant-supported crowns could also occur in adult patients.

Our results demonstrate that the annual growth increments of the anterior part of the craniofacial skeleton are small in the vast majority of individuals. From the perspective of implantologist/prosthodontist, changes taking place in the lower

facial compartment, i.e. between maxillary and mandibular planes (ANS to Me distance), are most important because the growth occurring here could directly lead to infraocclusion of the implant-crown. The growth changes taking place in the upper facial compartment (Nasion to ANS) have no direct influence on the position of the teeth. As presented in Figure 2, the mean yearly changes in the ANS-Me distance after 20 years of age are usually  $< 0.15$  mm for males and females. As a result, one could expect that the ANS-Me distance would increase by less than 1.5 mm over 10 years. Moreover, it should be realized that a 1.5 mm increase of ANS-Me distance would trigger teeth eruption in both maxillary and mandibular dental arches. The upper and lower front teeth would have to erupt by 0.75 mm to remain in occlusion. If a patient had a maxillary central incisor restored with an implant-supported crown, an ensuing 0.75 mm step between the incisal edges of implant-crown and adjacent teeth seems to be too small to cause any considerable esthetic problems. Moreover a replacement of the implant-crown is relatively straightforward. If a patient with a 0.75 mm infraocclusion wished to have a new crown made, it would be easy to replace.

The mean changes usually reported in the literature should not mislead the reader that each patient responds in a similar way. In fact, large variations in response to various treatment modalities are well known. Also, the longitudinal growth studies selected in this systematic review imply that a certain proportion of patients can have considerably more craniofacial growth after 20 years of age than the population mean. This may be the reason why our findings do not confirm the results of research [16] where the authors assessed patients who had had implants placed in the anterior region of the maxilla (esthetic zone). Twenty eight patients were divided into two groups consisting of 14 patients aged from 15.5 to 21 (“young group”) and 14 patients aged from 40 to 55 (“mature group”) at the time of implantation. Three years after implantation infraocclusion of the implant-crown was observed in the majority of patients from both the young and mature groups. Interestingly, the amount of infraocclusion was similar regardless of the patients’ age and gender. It is possible that selection bias, i.e. overrepresentation of subjects with considerable facial growth in adulthood, affected the results of this study by Bernard et al. Another explanation for the discrepancy between our findings and these observations [16] is that the subjects examined by Bernard and colleagues could have had inadequate occlusal contact between the teeth in the area of implantation. If the teeth did

not occlude properly, their eruption until occlusal contact is reached could be possible in the absence of craniofacial growth. Moreover, the number of patients in the groups in the study by Bernard et al. was small, which might have increased the randomness of the results.

As discussed before, replacement of an infraoccluded implant-crown is not difficult. Therefore elimination of one consequence of infraocclusion – the step between incisal edges – is uncomplicated. However, infraocclusion of the implant-crown can also lead to the alteration of the position and/or shape of the gingival margin. If it is disturbed recovery can be challenging, and the degree of difficulty depends on whether the defect is visible or not. Gingival defects which are not visible on smiling can usually be ignored (untreated). Defects in patients with gingival displays upon smiling will likely have to be treated by a prosthodontist and/or periodontist. Therefore, taking precautions to avoid problems with the contours of the gingival margin in patients with ‘gummy smile’ who need an implant-crown in the esthetic zone seems sensible. A simple preventive measure could be bonding an orthodontic wire retainer to the palatal surfaces of maxillary anterior teeth. The retainer holds the alignment of the teeth and does not permit the development of infraocclusion.

### Limitations

Craniofacial growth is not linear. Although we presented the mean annualized growth for the anterior part of the craniofacial skeleton, they should be considered as approximations only.

Infraocclusion of the implant-crown can occasionally occur in the absence of craniofacial growth in patients without proper occlusal contact between the maxillary and mandibular teeth. Unfortunately, selected studies did not provide any data to evaluate this issue.

### Conclusions

Based on the findings the following can be concluded: (1) the growth of the craniofacial skeleton after 17 years of age in males and 16 years of age in females is relatively small and should have a limited effect on the long-term esthetics of implant-crowns; (2) caution is recommended when considering implantation in patients with a gingival display upon smiling and those having inadequate occlusal contact between the maxillary and mandibular teeth.

*The extensive and detailed data referred to by the authors are available on request at their correspondence address.*

## Acknowledgements

### Conflict of interest statement

The authors declare that there is no conflict of interest in the authorship or publication of contribution.

### Funding sources

There are no sources of funding to declare.

## References

- [1] Jemt T, Lekholm U, Adell R. Osseointegrated implants in the treatment of partially edentulous patients: a preliminary study on 876 consecutively placed fixtures. *Int J Oral Maxillofac Implants*. 1989 Fall;4(3):241–7.
- [2] Palmer RM, Palmer PJ. Implant placement: surgical techniques and considerations. *Dent Update*. 1997 Sep;24(7):288–94.
- [3] Makkonen TA, Holmberg S, Nieni L, Olsson C, Tammissalo T, Peltola J. A 5-year prospective clinical study of Astra Tech dental implants supporting fixed bridges or overdentures in the edentulous mandible. *Clin Oral Implants Res*. 1997 Dec;8(6):469–75.
- [4] Branemark PI, Adell R, Breine U, Hansson BO, Lindstrom J, Ohlsson A. Intra-osseous anchorage of dental prostheses. Experimental studies. *Scand J Plast Reconstr Surg*. 1969;3(2):81–100
- [5] Centre for Reviews and Dissemination. Systematic Reviews. CRD's Guidance for Undertaking Reviews in Healthcare. University of York NHS Centre for Reviews & Dissemination. York; 2009.
- [6] Albrektsson T, Jansson T, Lekholm U. Osseointegrated dental implants. *Dent Clin North Am*. 1986 Jan;30(1):151–74.
- [7] Albrektsson T, Zarb GA. Current interpretations of the osseointegrated response: clinical significance. *Int J Prosthodont*. 1993 Mar-Apr;6(2):95–105.
- [8] Nentwig GH. Ankylosis implant system : concept and clinical application. *J Oral Implantology*. 2004;30(3):171–7.
- [9] Percinoto C, Vieira, AE, Barbieri CM, Melhado FL, Moreira KS. Use of dental implants in children: a literature review. *Quintessence Int*. 2001 May;32(5):381–3.
- [10] Mankani N, Chowdhary DR, Patil DB, Madalli DP. Dental implants in children and adolescents: A literature review. *J Oral Implantol*. 2012 Jan 3.
- [11] Oesterle LJ, Cronin RJ, Ranly DM. Maxillary implants and the growing patient. *Int J Oral Maxillofac Implants*. 1993;8(4):377–87.
- [12] Odman J, Grondahl K, Lekholm U, Thilander B. The effect of osseointegrated implants on the dento-alveolar development. A clinical and radiographic study in growing pigs. *Eur J Orthod*. 1991 Aug;13(4):279–86.
- [13] Thilander B, Odman J, Grondahl K, Friberg B. Osseointegrated implants in adolescents. An alternative in replacing missing teeth? *Eur J Orthod*. 1994 Apr;16(2):84–95.
- [14] Thilander B, Odman J, Gronghal K, Lekholm U. Aspects on osseointegrated implants inserted in growing jaws. A biometric and radiographic study in the young pigs. *Eur J Orthod*. 1992 Apr;14(2):99–109.
- [15] Behrents RG. The biological basis for understanding craniofacial growth during adulthood. *Prog Clin Biol Res*. 1985;187:307–19.
- [16] Iseri H, Solow B. Continued eruption of maxillary incisors and first molars in girls from 9 to 25 years, studied by the implant method. *Eur j Orthod*. 1996 Jun;18(3):245–56.
- [17] Bernard JP, Schatz JP, Christou P, Belser U, Kiliaridis S. Long-term vertical changes of the anterior maxillary teeth adjacent to single implants in young and mature adults. A retrospective study. *J Clin Periodontol*. 2004 Nov;31(11):1024–8.
- [18] Aarts BE, Convens J, Bronkhorst EM, Kuijpers-Jagtman AM, Fudalej PS. Cessation of facial growth in subjects with short, average, and long facial types – Implications for the timing of implant placement. *J Craniomaxillofac Surg*. 2015 Dec;43(10):2106–11.
- [19] Thilander B, Persson M, Adolfsson U. Roentgen-cephalometric standards for a Swedish population. A longitudinal study between the ages of 5 and 31 years. *Eur J Orthod*. 2005 Aug;27(4):370–89.
- [20] Bondemark L, Holmb AK, Hansen K, Axelsson S, Mohlin B, Brattstrom V, Pauling G, Pietilah T. Long-term stability of orthodontic treatment and patient satisfaction. A systematic review. *Angle Orthod*. 2007;77:181–91.
- [21] Deeks J, Glanville J, Sheldon T. Undertaking systematic reviews of research on effectiveness. CRD Guidance for those carrying out or commissioning reviews. York: NHS Centre for Reviews and Dissemination; 1996. CRD Report No 4.
- [22] Mohlin B, Axelsson S, Paulin G, Pietila T, Bondemark L, Brattstrom V, Hansen K, Holm AK. TMD in relation to malocclusion and orthodontic treatment. *Angle Orthod*. 2007;77:542–48.
- [23] Bondevik O. Growth changes in the cranial base and the face: a longitudinal cephalometric study of linear and angular changes in adult Norwegians. *Eur J Orthod*. 1995 Dec;17(6):525–32.
- [24] West K, McNamara J. Changes in the craniofacial complex from adolescence to midadulthood: A cephalometric study. *Am J Orthod and Dentofacial Orthopedics*. 1999 May;521–32.
- [25] De Lange GL. Aesthetic and prosthetic principles for the single tooth implant procedure: an overview. *Pract Periodontics Aesthet Dent*. 1995 Jan-Febr;7(1):51–61.
- [26] Garber D. The esthetic dental implant: letting restorations be the guide. *J Am Dent Assoc*. 1995 Mar;126(3):319.
- [27] Tarnow D, Eskow R. Considerations for single-unit esthetic implant restorations. *Compend Contin Educ Dent*. 1995 Aug;16(8):778–780.
- [28] Albrektsson T, Wennerberg A. The impact of oral implants – past and future 1966–2042. *Journal (Canadian Dental Association)*. 2005 May;71(5):327.
- [29] Akgul AA, Toygar TU. Natural craniofacial changes in the third decade of life: a longitudinal study. *Am J of Orthod and Dentofacial Orthopedics*. 2002 Nov;122(5):512–522.
- [30] Bishara S, Treder J, Jakobsen JR. Facial and dental changes in adulthood *Am J Orthod Dentofacial Orthop*. 1994 Aug;106(2):175–86
- [31] Foley TF, Duncan P. Soft tissue profile changes in late adolescent males. *Angle Orthod*. 1997;67(5):373–80.
- [32] Forsberg CM. Facial morphology and aging: a longitudinal cephalometric investigation of young adults. *Eur J of Orthodontics*. 1979;1(1):15–23.
- [33] Formby WA, Nanda RS, Currier GF. Longitudinal changes in the adult facial profile. *Am J of Orthodontics and Dentofacial Orthopedics*. 1994 May;105(5):464–76.
- [34] Fudalej P. Long-term changes of the upper lip position relative to the incisal edge. *Am J of Orthod and Dentofacial Orthopedics*. 2008 Feb;133(2):204–9.
- [35] Gormley JS, Richardson ME. Linear and angular changes in dento-facial dimensions in the third decade. *Brit J of Orthodontics*. 1999 Mar;26(1):51–55.

Acceptance for editing: 2017-01-20  
Acceptance for publication: 2017-03-10

### Correspondence address:

P. D. Fudalej  
ul. Słowackiego 25  
01-592 Warszawa  
phone: +48 603113317  
email: pawel@fudalej.com